

Asthma: Eosinophil Disease, Mast Cell Disease, or Both?

Peter Bradding, DM, FRCP

Although there is much circumstantial evidence implicating eosinophils as major orchestrators in the pathophysiology of asthma, recent studies have cast doubt on their importance. Not only does anti-interleukin-5 treatment not alter the course of the disease, but some patients with asthma do not have eosinophils in their airways, whereas patients with eosinophilic bronchitis exhibit a florid tissue eosinophilia but do not have asthma. In contrast, mast cells are found in all airways and localize specifically to key tissue structures such as the submucosal glands and airway smooth muscle within asthmatic bronchi, irrespective of disease severity or phenotype. Here they are activated and interact exclusively with these structural cells via adhesive pathways and through the release of soluble mediators acting across the distance of only a few microns. The location of mast cells within the airway smooth muscle bundles seems particularly important for the development and propagation of asthma, perhaps occurring in response to, and then serving to aggravate, an underlying abnormality in asthmatic airway smooth muscle function. Targeting this mast cell–airway smooth muscle interaction in asthma offers exciting prospects for the treatment of this common disease.

Key words: *asthma, eosinophil, mast cell*

Asthma Immunopathology

Asthma is a complex immunologic and inflammatory disease characterized by the presence of airway inflammation, airway wall remodelling, and bronchial hyperresponsiveness (BHR). Exactly how these three features interact and whether they are dependent on each other for their occurrence is not clear. Although this article focuses on the role of mast cells and eosinophils in asthma pathogenesis, it is important to appreciate that most, if not all, elements of the asthmatic airway are dysfunctional. There is epithelial damage with failure of healing and overproduction of growth factors and proinflammatory cytokines,¹ mucous gland hyperplasia with associated mucus hypersecretion,² airway smooth muscle (ASM) remodelling with hypertrophy, hyperplasia, BHR and cytokine secretion,^{3–5} and activation of inflammatory cells, including mast cells,⁶ T cells,⁷ eosinophils,⁸ and neutrophils.² The current cornerstone of asthma management is the use of inhaled corticosteroids, which are efficacious in approximately 90% of patients because they attenuate many of these diverse pathologic features.⁹ However, for the remaining

10% of patients, these drugs are of poor efficacy for reasons that are not well understood. There is therefore an unmet clinical need for novel modulators of inflammation and tissue remodelling with different mechanisms of action and/or adverse-effect profiles from existing drugs. A better understanding of the factors orchestrating the immunopathology of asthma is therefore vital if this is to be achieved.

Eosinophilic Inflammation in Asthma

It was recognized many years ago in post-mortem studies that airway mucosal infiltration by eosinophils is a common feature in patients dying from asthma.¹⁰ More recently, studies performed on bronchial biopsies obtained at bronchoscopy demonstrated increased numbers of eosinophils in the epithelium and lamina propria of even mild asthmatics when compared with normal subjects.^{8,11} The late asthmatic reaction (LAR) following laboratory allergen challenge is characterized physiologically by airway narrowing and increased BHR.¹² Accompanying this is an influx of eosinophils, and it has been proposed that this eosinophil infiltration contributes to the LAR and associated physiological abnormalities. In vitro, eosinophil-derived major basic protein, eosinophil cationic protein, and eosinophil peroxidase are cytotoxic to the respiratory epithelium.^{13,14} Elevated levels of these products can be measured in the sputum of asthmatics,¹⁵ in bronchoalveolar lavage (BAL) fluid,¹⁶ and around areas of

Peter Bradding: *Department of Infection, Immunity and Inflammation, Institute for Lung Health, University of Leicester, UK.*

Correspondence to: Professor Peter Bradding, *Department of Respiratory Medicine, Glenfield Hospital, Groby Road, Leicester, LE3 9QP UK; e-mail:* pbradding@hotmail.com.

DOI 10.2310/7480.2008.00011

damaged epithelium post-mortem,¹⁷ suggesting that airway eosinophils are activated and may be an important mediator of epithelial damage. Eosinophils also release bronchoconstrictor mediators such as leukotriene C₄ (LTC₄), which are elevated during the LAR, and more recently, they have been shown to be a source of numerous chemokines and cytokines, including interleukin (IL)-4,¹⁸ IL-5,¹⁹ and IL-13,²⁰ suggesting that they have important roles in the immunopathology of the disease.

Interestingly, when considering asthma as a whole, the inflammatory and remodelling changes are remarkably similar irrespective of how the disease is classified, for example, atopic, non-atopic, or occupational.^{21–24} However, there are clear differences between individual subjects with asthma that until recently have been overlooked. It is evident looking at the distribution of eosinophil counts in Figure 1 that although their numbers are increased overall in the epithelium and lamina propria of the steroid-naïve asthmatic group, there is a wide range, and about 25% of subjects have cell counts similar to those of subjects without asthma.⁸ These observations have also been made in studies looking at induced sputum, where again about 25% of steroid-naïve asthmatic subjects can be considered to be non-eosinophilic.²⁵ In severe asthma, patients can be divided into eosinophil positive or negative²⁶ with the presence of mucosal eosinophils plus neutrophils or neutrophils alone. Interestingly, those severe patients with a mucosal eosinophilia exhibit deposition of collagen in the lamina reticularis, whereas those subjects without eosinophils do not.²⁶ Thus, in

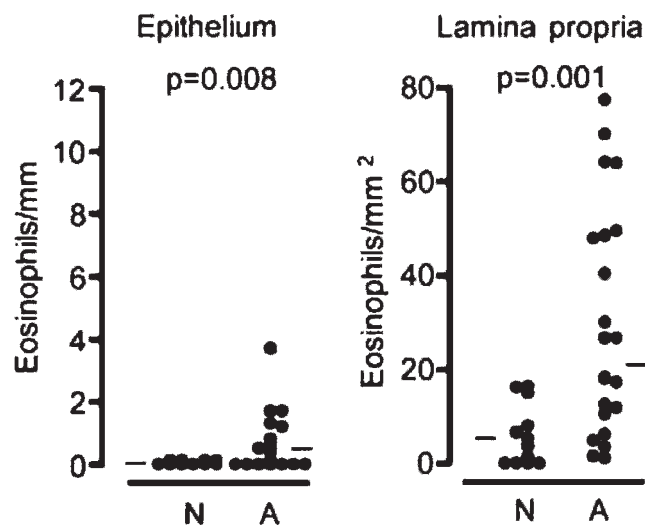


Figure 1. Eosinophil counts in the bronchial epithelium and lamina propria in normal subjects (N) and patients with mild steroid-naïve asthma (A). Adapted from Bradding P et al.⁸

severe disease, there is heterogeneity in terms of both the pathology and the inflammatory response. A recent bronchoscopy study in mild steroid-naïve asthmatics classified as eosinophilic or non-eosinophilic based on the induced sputum cell profile has revealed similar findings.²⁷ These observations indicate that although eosinophils are often present across the spectrum of asthma severity, about 25% of patients have active disease in their absence, so they cannot be an essential requirement for disease expression.

Further evidence against a critical role for eosinophils in day-to-day asthma symptoms has come from studies with anti-IL-5 antibody treatment.^{28–31} Anti-IL-5 antibodies are very effective at reducing sputum and blood eosinophil counts and reduce tissue eosinophils by approximately 60%. However, in spite of this, asthma symptoms continue unabated, and BHR does not improve. Furthermore, there is no attenuation of the airway response to experimental allergen challenge, suggesting that eosinophils are also not important for this.²⁹ It has been argued that a 60% reduction in eosinophils within the tissue may not be adequate to reduce their pathologic effects, but this seems unlikely because the reduction in eosinophils correlates strongly with a reduction in the deposition of tenascin, lumican, and procollagen III in the lamina reticularis.³²

Eosinophils, Asthma Exacerbations, and Steroid Responsiveness

Although the role eosinophils play in the pathophysiology of asthma is unclear, they represent an excellent biomarker for predicting whether patients will respond to corticosteroids, predicting which patients are at risk of exacerbations, and for guiding steroid therapy with a view to preventing these events. Several studies have shown that steroid-naïve asthmatic patients with a sputum eosinophilia have an excellent clinical response to inhaled corticosteroids, whereas non-eosinophilic patients do not.^{25,27} The presence of eosinophils is also a good predictor of whether a patient is at risk of asthma exacerbations, and keeping the sputum eosinophil count suppressed through the appropriate use of inhaled or oral corticosteroids reduces the number of severe exacerbations in patients with severe disease by about 60%.³³ Whether eosinophils play a role in the pathophysiology of acute exacerbations is still not known as the previous anti-IL-5 studies were not powered to test this. There was a non-significant trend toward reduced asthma exacerbations in one anti-IL-5 trial.³¹ A further ongoing clinical trial limited to patients

with eosinophilic asthma is looking at the effects of anti-IL-5 on asthma exacerbations as the primary end point.

Mast Cells in Asthma

Mast cells have long been considered to play a significant role in the pathophysiology of asthma through their ability to release a host of pleiotropic autacoid mediators, proteases, and cytokines in response to activation by both immunoglobulin E (IgE)-dependent and diverse non-immunologic stimuli.^{6,34} Within the first few minutes following laboratory allergen challenge, secretion of the autacoid mediators histamine, prostaglandin D₂ (PGD₂) and LTC₄ induces bronchoconstriction, mucus secretion, and mucosal edema, which account for the acute symptoms.³⁵ Mast cells also release preformed and newly generated cytokines with the potential for a wide range of biological effects in the airways. For example, these include IL-4 and IL-13, which both induce ASM hyperresponsiveness, IgE synthesis, and eosinophil recruitment, and IL-5, an important eosinophil growth factor.⁶ In addition, the mast cell is a source of several neutral proteases, such as tryptase and chymase, which interact with many cells and potentially contribute to airway wall remodelling.⁶ Tumour necrosis factor α (TNF- α) is another proinflammatory cytokine secreted by mast cells that is strongly implicated in the pathogenesis of asthma. TNF- α expression is increased in the airways of both mild and severe asthmatics,^{8,36} largely owing to increased expression by mucosal mast cells. When administered by inhalation to humans, it induces both BHR and sputum neutrophilia in normal subjects and exacerbates BHR in patients with asthma,^{37,38} whereas anti-TNF- α therapy is effective treatment in some patients with refractory disease.^{36,39}

In chronic asthma, mast cells within the bronchial mucosa are persistently activated with evidence of continuous mediator release and cytokine synthesis.^{11,16,23,40} This is apparent from increased concentrations of mast cell-specific mediators such as tryptase in BAL, increased cell-associated cytokine messenger ribonucleic acid and protein expression, and degranulation visualized in situ using electron microscopy. It is often assumed that this activation is driven by allergen, but it is important to appreciate that mast cells can be activated by numerous diverse stimuli, including monomeric IgE alone,³⁴ proteases (including tryptase),^{41,42} cytokines (eg, stem cell factor, TNF- α , interferon- γ),⁴³⁻⁴⁵ complement (C5a),⁴⁶ Toll-like receptor ligands,^{45,47,48} immunoglobulin light chains,⁴⁹ and hyperosmolality⁵⁰ (Figure 2). Many of these are relevant to the complex inflammatory milieu of

the asthmatic airway. Furthermore, the ultrastructural appearance of mast cells in asthmatic airways often indicates a process of piecemeal degranulation rather than the anaphylactic degranulation evident after allergen challenge.¹¹ This supports the view that allergen-independent mechanisms of mast cell activation are important.

Mast Cell Tissue Microlocalization in Asthma

Mast cells are found adjacent to blood vessels in the lamina propria in normal human airways, but in asthma, they migrate into three key structures: the airway epithelium,⁸ the airway mucous glands,² and the ASM.⁵¹ This anatomical relocation places activated mast cells deep within these dysfunctional airway elements, suggesting that the targeted delivery of their mediators is likely to be central to the disordered airway physiology.

Infiltration of the bronchial epithelium by mast cells in asthma may be important for disease pathogenesis for several reasons. First, mast cells are placed at the portal of entry of noxious stimuli such as aeroallergens, which might facilitate an effector role in the ongoing immunologic response (antigen presentation, T-helper 2 [Th2] cell differentiation, IgE synthesis).⁵² Second, there are likely to be important consequences of mast cell degranulation on epithelial function. For example, mast cells adhere avidly to bronchial epithelial cells,⁵³ and tryptase stimulates airway epithelial IL-8 release and can upregulate intercellular adhesion molecule 1 expression.⁵⁴ At this site, mast cells might also respond more readily to other stimuli, for example, hyperosmolality of the airway lining fluid induced by exercise, or inhaled bronchoconstrictors, such as adenosine. Interestingly, monolayers of bronchial epithelium actually inhibit IgE-dependent human lung mast cell mediator release.⁵⁵ Thus, resting intact airway epithelium may act as a suppressor of mast cell activation, an effect that is lost when the airway epithelium is damaged.

Severe mucus plugging is a well-known feature of severe fatal asthma but is also recognized as a feature of milder disease^{2,56} and results from mucus hypersecretion by hyperplastic submucosal glands and epithelial goblet cells. Mast cells specifically infiltrate the mucosal gland stroma in asthma and exhibit features of degranulation.² Their numbers also correlate with the degree of mucus obstruction in the airways. Taken together, this suggests a role for mast cells in the development of mucous gland hyperplasia and the mucous gland hypersecretion characteristic of asthma. Numerous mast cell products are likely to contribute to these features of asthma, including

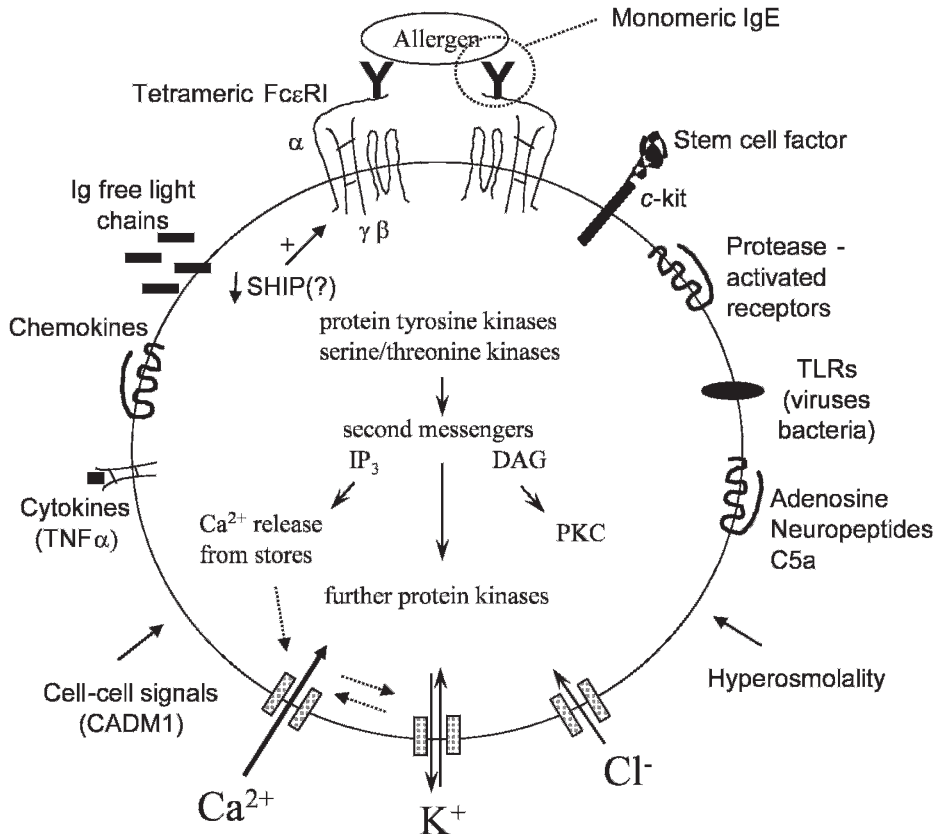


Figure 2. Potential mechanisms of mast cell activation in asthmatic airways.

histamine, PGD_2 , LTC_4 , IL-6, IL-13, $\text{TNF-}\alpha$, tryptase, chymase, and amphiregulin.⁶

Mast Cell Infiltration of the ASM as a Key Determinant of the Asthmatic Phenotype: Pathologic Comparison of Asthma with Eosinophilic Bronchitis

Eosinophilic bronchitis is a common cause of cough and is characterized by the presence of a sputum eosinophilia occurring in the absence of variable airflow obstruction or BHR.⁵⁷ A detailed comparison of the immunopathology of asthma and eosinophilic bronchitis has revealed an identical pathology in terms of T-cell and eosinophil infiltration, mucosal mast cell density, Th2 cytokine expression, epithelial integrity, sub-basement membrane collagen deposition, and mediator concentrations, including histamine and PGD_2 .^{51,58,59} This suggests that many of the immunopathologic features previously attributed to causing asthma may not be as important for the development of airflow obstruction, BHR, and remodeling as previously suggested. It also demonstrates that it is

possible to have florid eosinophilic airway inflammation in the absence of asthma.

The striking difference between the pathology of asthma and eosinophilic bronchitis is present within the ASM bundles. In asthmatic subjects, there are numerous mast cells within the ASM, but these are rarely seen in the ASM of patients with eosinophilic bronchitis or normal subjects.⁵¹ The majority of these mast cells are of the MC_{TC} phenotype containing both tryptase and chymase. The number of mast cells in the ASM bundles correlates with the severity of BHR within the asthmatic group, supporting the view that this observation is of functional relevance. Our initial study failed to identify T cells or eosinophils in the smooth muscle of any of the study groups, although a more recent study has claimed to identify the presence of some T cells.⁶⁰ The findings related to mast cells have been confirmed by several independent groups,^{60–64} and it has recently been shown that the mast cells within the ASM bundles in asthma demonstrate ultrastructural features of activation.⁶⁰ We have also extended our work to look across asthma phenotypes. Interestingly, ASM infiltration by mast cells is a feature of both eosinophilic and non-eosinophilic asthma, again

supporting the view that this is a fundamental abnormality in asthma.²⁷

Functional Consequences of ASM Infiltration by Mast Cells

Human lung mast cells adhere to ASM cells,⁶⁵ in part through the immunoglobulin superfamily member cell adhesion molecule 1 (previously known as tumour suppressor in lung cancer 1). This, coupled with the observation that mast cells within the ASM bundles are activated, suggests that there is an intimate relationship between the two cell types. Numerous mast cell-derived mediators directly affect ASM function both in vitro and in vivo. Histamine, PGD₂ and LTC₄ are all potent agonists for ASM contraction, whereas tryptase potentiates the contractile response of sensitized bronchi to histamine⁶⁶ and induces proliferation of human ASM.^{67,68} IL-4 and IL-13 induce BHR when instilled into the airways of mice,⁶⁹ and of note, both of these cytokines are expressed by mast cells within the asthmatic ASM.⁷⁰ Several potential mechanisms for the recruitment of mast cells by the ASM have been identified,^{5,62,71} but the CXCL10-CXCR3 axis looks particularly important.^{5,71} Targeting mast cell migration through these specific chemokine pathways or through a more generalized approach⁷² may therefore provide a novel means for inhibiting the interaction of mast cells with the ASM.

In summary, although there is much circumstantial evidence implicating eosinophils as major orchestrators in the pathophysiology of asthma, recent studies have cast doubt on their importance. Not only does anti-IL-5 treatment not alter the course of the disease, but some patients with asthma do not have eosinophils in their airways, whereas patients with eosinophilic bronchitis exhibit a florid tissue eosinophilia but do not have asthma. In contrast, mast cells are found in all airways and localize specifically to key tissue structures, such as the submucosal glands and ASM within asthmatic bronchi, irrespective of disease severity or phenotype. Here they are activated and interact exclusively with these structural cells via adhesive pathways and through the release of soluble mediators acting across the distance of only a few microns. The location of mast cells within the ASM bundles seems particularly important for the development and propagation of asthma, perhaps occurring in response to, and then serving to aggravate, an underlying abnormality in the behaviour of asthmatic ASM. Targeting this mast cell-ASM interaction in asthma offers exciting prospects for the treatment of this common disease.

References

- Holgate ST, Lackie PM, Davies DE, et al. The bronchial epithelium as a key regulator of airway inflammation and remodelling in asthma. *Clin Exp Allergy* 1999;29 Suppl 2:90–5.
- Carroll NG, Mutavdzic S, James AL. Increased mast cells and neutrophils in submucosal mucous glands and mucus plugging in patients with asthma. *Thorax* 2002;57:677–82.
- Ebina M, Yaegashi H, Chiba R, et al. Hyperreactive site in the airway tree of asthmatic patients revealed by thickening of bronchial muscles. A morphometric study. *Am Rev Respir Dis* 1990;141:1327–32.
- Ebina M, Takahashi T, Chiba T, Motomiya M. Cellular hypertrophy and hyperplasia of airway smooth muscles underlying bronchial asthma. A 3-D morphometric study. *Am Rev Respir Dis* 1993;148:720–6.
- Brightling CE, Ammit AJ, Kaur D, et al. The CXCL10/CXCR3 axis mediates human lung mast cell migration to asthmatic airway smooth muscle. *Am J Respir Crit Care Med* 2005;171:1103–8.
- Bradding P, Walls AF, Holgate ST. The role of the mast cell in the pathophysiology of asthma. *J Allergy Clin Immunol* 2006;117:1277–84.
- Robinson DS, Hamid Q, Ying S, et al. Predominant TH2-like bronchoalveolar T-lymphocyte population in atopic asthma. *N Engl J Med* 1992;326:298–304.
- Bradding P, Roberts JA, Britten KM, et al. Interleukin-4, -5, and -6 and tumor necrosis factor-alpha in normal and asthmatic airways: evidence for the human mast cell as a source of these cytokines. *Am J Respir Cell Mol Biol* 1994;10:471–80.
- Barnes PJ, Adcock IM. How do corticosteroids work in asthma? *Ann Intern Med* 2003;139:359–70.
- Huber HL, Koessler KK. The pathology of bronchial asthma. *Arch Intern Med* 1922;30:689–95.
- Beasley R, Roche WR, Roberts JA, Holgate ST. Cellular events in the bronchi in mild asthma and after bronchial provocation. *Am Rev Respir Dis* 1989;139:806–17.
- Bradding P, Walls AF, Church MK. Mast cells and basophils: their role in initiating and maintaining inflammatory responses. In: Holgate ST, editor. *Immunopharmacology of the respiratory system*. London: Academic Press; 1995. p. 53–84.
- Motojima S, Frigas E, Loegering DA, Gleich GJ. Toxicity of eosinophil cationic proteins for guinea pig tracheal epithelium in vitro. *Am Rev Respir Dis* 1989;139:801–5.
- Ayars GH, Altman LC, McManus MM, et al. Injurious effect of the eosinophil peroxidase-hydrogen peroxide-halide system and major basic protein on human nasal epithelium in vitro. *Am Rev Respir Dis* 1989;140:125–31.
- Frigas E, Loegering DA, Solley GO, et al. Elevated levels of the eosinophil granule major basic protein in the sputum of patients with bronchial asthma. *Mayo Clin Proc* 1981;56:345–53.
- Broide DH, Gleich GJ, Cuomo AJ, et al. Evidence of ongoing mast cell and eosinophil degranulation in symptomatic asthma airway. *J Allergy Clin Immunol* 1991;88:637–48.
- Filley WV, Holley KE, Kephart GM, Gleich GJ. Identification by immunofluorescence of eosinophil granule major basic protein in lung tissues of patients with bronchial asthma. *Lancet* 1982 3;2:11–6.
- Bradding P, Feather IH, Wilson S, et al. Cytokine immunoreactivity in seasonal rhinitis: regulation by a topical corticosteroid. *Am J Respir Crit Care Med* 1995;151:1900–6.

19. Dubucquoi S, Desreumaux P, Janin A, et al. Interleukin 5 synthesis by eosinophils: association with granules and immunoglobulin-dependent secretion. *J Exp Med* 1994;179:703–8.
20. Schmid-Grendelmeier P, Altnauer F, Fischer B, et al. Eosinophils express functional IL-13 in eosinophilic inflammatory diseases. *J Immunol* 2002;169:1021–7.
21. Humbert M, Durham SR, Ying S, et al. IL-4 and IL-5 mRNA and protein in bronchial biopsies from patients with atopic and nonatopic asthma: evidence against “intrinsic” asthma being a distinct immunopathologic entity. *Am J Respir Crit Care Med* 1996;154:1497–504.
22. Humbert M, Grant JA, Taborda-Barata L, et al. High-affinity IgE receptor (FcεRI)-bearing cells in bronchial biopsies from atopic and nonatopic asthma. *Am J Respir Crit Care Med* 1996;153:1931–7.
23. Ying S, Humbert M, Barkans J, et al. Expression of IL-4 and IL-5 mRNA and protein product by CD4+ and CD8+ T cells, eosinophils, and mast cells in bronchial biopsies obtained from atopic and nonatopic (intrinsic) asthmatics. *J Immunol* 1997;158:3539–44.
24. Frew AJ, Chan H, Lam S, Chan-Yeung M. Bronchial inflammation in occupational asthma due to Western red cedar. *Am J Respir Crit Care Med* 1995;151:340–4.
25. Green RH, Brightling CE, Woltmann G, et al. Analysis of induced sputum in adults with asthma: identification of subgroup with isolated sputum neutrophilia and poor response to inhaled corticosteroids. *Thorax* 2002;57:875–9.
26. Wenzel SE, Schwartz LB, Langmack EL, et al. Evidence that severe asthma can be divided pathologically into two inflammatory subtypes with distinct physiologic and clinical characteristics. *Am J Respir Crit Care Med* 1999;160:1001–8.
27. Berry MA, Morgan A, Shaw DE, et al. Pathological features and inhaled corticosteroid response of eosinophilic and non-eosinophilic asthma. *Thorax* 2007;62:1043–9.
28. O’Byrne PM. Cytokines or their antagonists for the treatment of asthma. *Chest* 2006;130:244–50.
29. Leckie MJ, ten Brinke A, Khan J, et al. Effects of an interleukin-5 blocking monoclonal antibody on eosinophils, airway hyperresponsiveness, and the late asthmatic response. *Lancet* 2000;356:2144–8.
30. Kips JC, O’Connor BJ, Langley SJ, et al. Effect of SCH55700, a humanized anti-human interleukin-5 antibody, in severe persistent asthma: a pilot study. *Am J Respir Crit Care Med* 2003;167:1655–9.
31. Flood-Page P, Swenson C, Faiferman I, et al. A study to evaluate safety and efficacy of mepolizumab in patients with moderate persistent asthma. *Am J Respir Crit Care Med* 2007;176:1062–71.
32. Flood-Page P, Menzies-Gow A, Phipps S, et al. Anti-IL-5 treatment reduces deposition of ECM proteins in the bronchial subepithelial basement membrane of mild atopic asthmatics. *J Clin Invest* 2003;112:1029–36.
33. Green RH, Brightling CE, McKenna S, et al. Asthma exacerbations and eosinophil counts. A randomised controlled trial. *Lancet* 2002;360:1715–21.
34. Cruse G, Kaur D, Yang W, et al. Activation of human lung mast cells by monomeric immunoglobulin E. *Eur Respir J* 2005;25:858–63.
35. Bradding P. Mast cells in asthma. In: Busse WW, Holgate ST, editors. *Asthma & rhinitis*. Boston: Blackwell Scientific Publications; 2000. p. 319–38.
36. Howarth PH, Babu KS, Arshad HS, et al. Tumour necrosis factor (TNF{α}) as a novel therapeutic target in symptomatic corticosteroid-dependent asthma. *Thorax* 2005;60:1012–8.
37. Thomas PS, Yates DH, Barnes PJ. Tumor necrosis factor-α increases airway responsiveness and sputum neutrophilia in normal human subjects. *Am J Respir Crit Care Med* 1995;152:76–80.
38. Thomas PS, Heywood G. Effects of inhaled tumour necrosis factor α in subjects with mild asthma. *Thorax* 2002;57:774–8.
39. Berry MA, Hargadon B, Shelley M, et al. Evidence of a role of TNFα in refractory asthma. *N Engl J Med* 2006;354:697–708.
40. Flint KC, Leung KB, Hudspeth BN, et al. Bronchoalveolar mast cells in extrinsic asthma: a mechanism for the initiation of antigen specific bronchoconstriction. *Br Med J* 1985;291:923–6.
41. He S, Aslam A, Gaca MD, et al. Inhibitors of tryptase as mast cell-stabilizing agents in the human airways: effects of tryptase and other agonists of proteinase-activated receptor 2 on histamine release. *J Pharmacol Exp Ther* 2004;309:119–26.
42. Machado DC, Horton D, Harrop R, et al. Potential allergens stimulate the release of mediators of the allergic response from cells of mast cell lineage in the absence of sensitization with antigen-specific IgE. *Eur J Immunol* 1996;26:2972–80.
43. Frenz AM, Gibbs BF, Pearce FL. The effect of recombinant stem cell factor on human skin and lung mast cells and basophil leukocytes. *Inflamm Res* 1997;46:35–9.
44. Coward WR, Okayama Y, Sagara H, et al. NF-κB and TNF-α: a positive autocrine loop in human lung mast cells? *J Immunol* 2002;169:5287–93.
45. Okumura S, Kashiwakura J, Tomita H, et al. Identification of specific gene expression profiles in human mast cells mediated by Toll-like receptor 4 and FcεRI. *Blood* 2003;102:2547–54.
46. Oskeritzian CA, Zhao W, Min HK, et al. Surface CD88 functionally distinguishes the MCTC from the MCT type of human lung mast cell. *J Allergy Clin Immunol* 2005;115:1162–8.
47. Kulka M, Alexopoulou L, Flavell RA, Metcalfe DD. Activation of mast cells by double-stranded RNA: evidence for activation through Toll-like receptor 3. *J Allergy Clin Immunol* 2004;114:174–82.
48. McCurdy JD, Olynych TJ, Maher LH, Marshall JS. Cutting edge: distinct Toll-like receptor 2 activators selectively induce different classes of mediator production from human mast cells. *J Immunol* 2003;170:1625–9.
49. Kraneveld AD, Kool M, van Houwelingen AH, et al. Elicitation of allergic asthma by immunoglobulin free light chains. *Proc Natl Acad Sci U S A* 2005;102:1578–83.
50. Eggleston PA, Kagey-Sobotka A, Schleimer RP, et al. Interaction between hyperosmolar and IgE-mediated histamine release from basophils and mast cells. *Am Rev Respir Dis* 1984;130:86–91.
51. Brightling CE, Bradding P, Symon FA, et al. Mast cell infiltration of airway smooth muscle in asthma. *N Engl J Med* 2002;346:1699–705.
52. Bradding P, Holgate ST. Immunopathology and human mast cell cytokines. *Crit Rev Oncol Haematol* 1999;31:119–33.
53. Sanmugalingam D, Wardlaw AJ, Bradding P. Adhesion of human lung mast cells to bronchial epithelium: evidence for a novel carbohydrate-mediated mechanism. *J Leuk Biol* 2000;68:38–46.
54. Cairns JA, Walls AF. Mast cell tryptase is a mitogen for epithelial cells. Stimulation of IL-8 production and intercellular adhesion molecule-1 expression. *J Immunol* 1996;156:275–83.
55. Yang W, Wardlaw AJ, Bradding P. Attenuation of human lung mast cell degranulation by bronchial epithelium. *Allergy* 2006;61:569–75.

56. Cutz E, Levison H, Cooper DM. Ultrastructure of airways in children with asthma. *Histopathology* 1978;2:407–21.
57. Brightling CE, Ward R, Goh KL, et al. Eosinophilic bronchitis is an important cause of chronic cough. *Am J Respir Crit Care Med* 1999;160:406–10.
58. Brightling CE, Symon FA, Birring SS, et al. Comparison of airway immunopathology of eosinophilic bronchitis and asthma. *Thorax* 2003;58:528–32.
59. Brightling CE, Symon FA, Birring SS, et al. TH2 cytokine expression in bronchoalveolar lavage fluid T lymphocytes and bronchial submucosa is a feature of asthma and eosinophilic bronchitis. *J Allergy Clin Immunol* 2002;110:899–905.
60. Begueret H, Berger P, Vernejoux JM, et al. Inflammation of bronchial smooth muscle in allergic asthma. *Thorax* 2007;62:8–15.
61. Amin K, Janson C, Boman G, Venge P. The extracellular deposition of mast cell products is increased in hypertrophic airways smooth muscles in allergic asthma but not in nonallergic asthma. *Allergy* 2005;60:1241–7.
62. Berger P, Girodet PO, Begueret H, et al. Tryptase-stimulated human airway smooth muscle cells induce cytokine synthesis and mast cell chemotaxis. *FASEB J* 2003;17:2139–41.
63. El-Shazly A, Berger P, Girodet PO, et al. Fractalkine produced by airway smooth muscle cells contributes to mast cell recruitment in asthma. *J Immunol* 2006;176:1860–8.
64. Carroll NG, Mutavdzic S, James AL. Distribution and degranulation of airway mast cells in normal and asthmatic subjects. *Eur Respir J* 2002;19:879–85.
65. Yang W, Kaur D, Okayama Y, et al. Human lung mast cells adhere to human airway smooth muscle, in part, via tumor suppressor in lung cancer-1. *J Immunol* 2006;176:1238–43.
66. Berger P, Compton SJ, Molimard M, et al. Mast cell tryptase as a mediator of hyperresponsiveness in human isolated bronchi. *Clin Exp Allergy* 1999;29:804–12.
67. Berger P, Perng DW, Thabrew H, et al. Tryptase and agonists of PAR-2 induce the proliferation of human airway smooth muscle cells. *J Appl Physiol* 2001;91:1372–9.
68. Brown JK, Jones CA, Rooney LA, et al. Tryptase's potent mitogenic effects in human airway smooth muscle cells are via non-proteolytic actions. *Am J Physiol Lung Cell Mol Physiol* 2002;282:L197–206.
69. Venkayya R, Lam M, Willkom M, et al. The Th2 lymphocyte products IL-4 and IL-13 rapidly induce airway hyperresponsiveness through direct effects on resident airway cells. *Am J Respir Cell Mol Biol* 2002;26:202–8.
70. Brightling CE, Symon FA, Holgate ST, et al. IL-4 and IL-13 are co-localised to mast cells within airway smooth muscle in asthma. *Clin Exp Allergy* 2003;33:1711–6.
71. Brightling CE, Kaur D, Berger P, et al. Differential expression of CCR3 and CXCR3 by human lung and bone marrow-derived mast cells: implications for tissue mast cell migration. *J Leuk Biol* 2005;77:759–66.
72. Cruse G, Duffy SM, Brightling CE, Bradding P. Functional KCa3.1 K⁺ channels are required for human lung mast cell migration. *Thorax* 2006;61:880–5.